



TECHNICAL UNIVERSITY OF MOMBASA

FACULTY OF APPLIED AND HEALTH SCIENCES

DEPARTMENT OF MEDICAL SCIENCES

UNIVERSITY EXAMINATION FOR:

BMLS

AML 4420 : MEDICAL LABORATORY PRACTICALS

END OF SEMESTER EXAMINATION

SERIES: APRIL 2016

TIME: 3 HOURS

DATE: Pick Date May 2016

Instructions to Candidates

You should have the following for this examination

-Answer Booklet, examination pass and student ID

This paper consists of **SIX** Question(s). Attempt ALL questions.

Do not write on the question paper.

Question 1 (Microbiology).

The culture plate labelled **M1** was obtained from a throat swab of a patient.

- Describe the bacterial colonies (4 Marks)
- Using the provided reagents attempt to identify the organism (s) (12 Marks)
- List two other infections that can be caused by the bacteria (4 Marks)

SPOTS

Spot I.

- Identify the spot labelled **M2** (1 Mark)
- Name at least 3 pathogens which can be isolated from the specimen (3 marks)
- Name the Medium which is used to culture the specimen (1 mark)

Spot II.

- i) Identify the spot labelled **M3** (2 marks)
- ii) Name the bacteria which is isolated using the medium (1 mark)
- iii) Name the specimen cultured in the medium (1 mark)
- iv) Name the staining procedure which is used in identifying the pathogen (1 mark)

Question 2 (Clinical Chemistry)

. You are provided with a urine specimen labelled “B” from a patient for routine medical check-up. With reagents and apparatus provided.

- i) Perform urinalysis and record your findings (10 marks)
- ii) Write a brief procedure (7 marks)
- iii) Suggest possible causes of the findings in “ii” above. (3 marks)
- iv) Where possible give the different types of analytes with elevated values (2 marks)

SPOTS

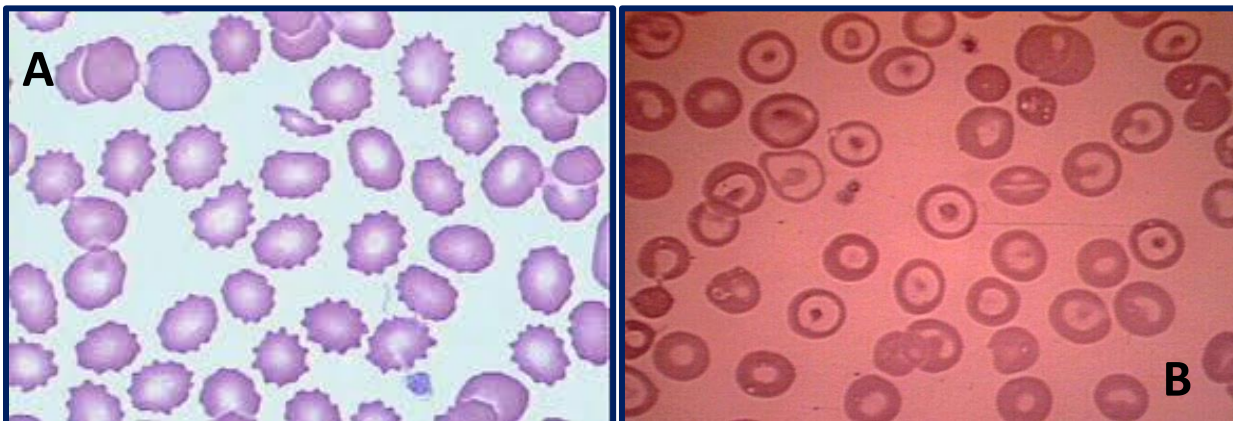
Spot III

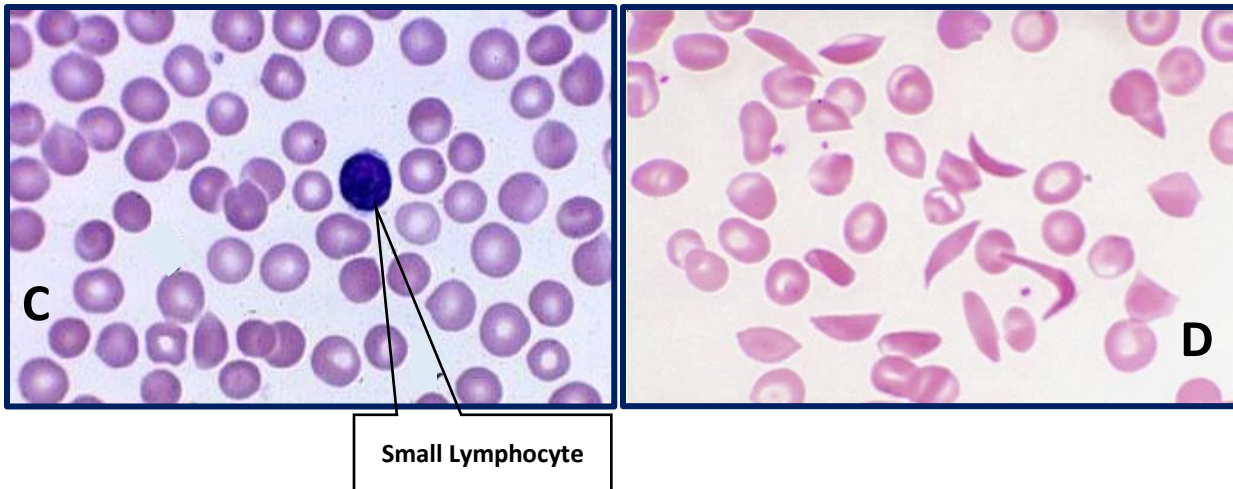
- i) Name the spot (2 marks)
- ii) Give one use of the spot (2 marks)

Spot IV

- i) Name the spot (2 marks)
- ii) Give one use of the spot (2 marks)

Question 3 (Haematology)





- List down the eight (8) red cell abnormalities in the Micrographs above (8mks)
- Name one disease condition that may lead to the identified abnormalities (16mks)
- Discuss the pathophysiology associated with any two of the conditions in the micrographs (6mks)

Question 4 (blood transfusion)

A Patient blood group was reviewed two weeks post-partum and it was realized that she was RhD Neg while the newborn was RhD pos.

- With apparatus and reagents provided determine if the mother was sensitized during delivery. (20mks)

SPOTS

Spot V (5mks)

- Identify the spot labelled I
- State its use in the blood transfusion laboratory
- List one advantage and two disadvantages of using the anticoagulant

Spot VI (5mks)

- What are the contents in the bag labelled II
- State three reasons why it cannot be used
- What is the recommended method of disposal?

Question five (Histology)

You have been provided with a tissue section on a slide marked H. with reagents provided, stain and report on your findings (15mks)

SPOTS

Spot VII

- i. Name the spot (1mk)
- ii. Give one use of the spot (1mk)
- iii. Name five parts of the spot and their functions (10mks)

SPOT VIII

- i. Name the spot (1mk)
- ii. Give the functions of the spot (1mk)
- iii. Give one alternative of the spot (1mk)

Question 6 (Parasitology)

You are provided with stool specimen labelled S using the reagents and apparatus provided.

Carry out laboratory procedure and report your findings. (20marks)

SPOTS

Spot IX

- i. Identify the spot (2.5 marks)
- ii. What is its medical importance (2.5marks)

Spot X

Identify the spot (2.5marks)

What is its medical importance (2.5marks)